

Subconjunctival silicone oil

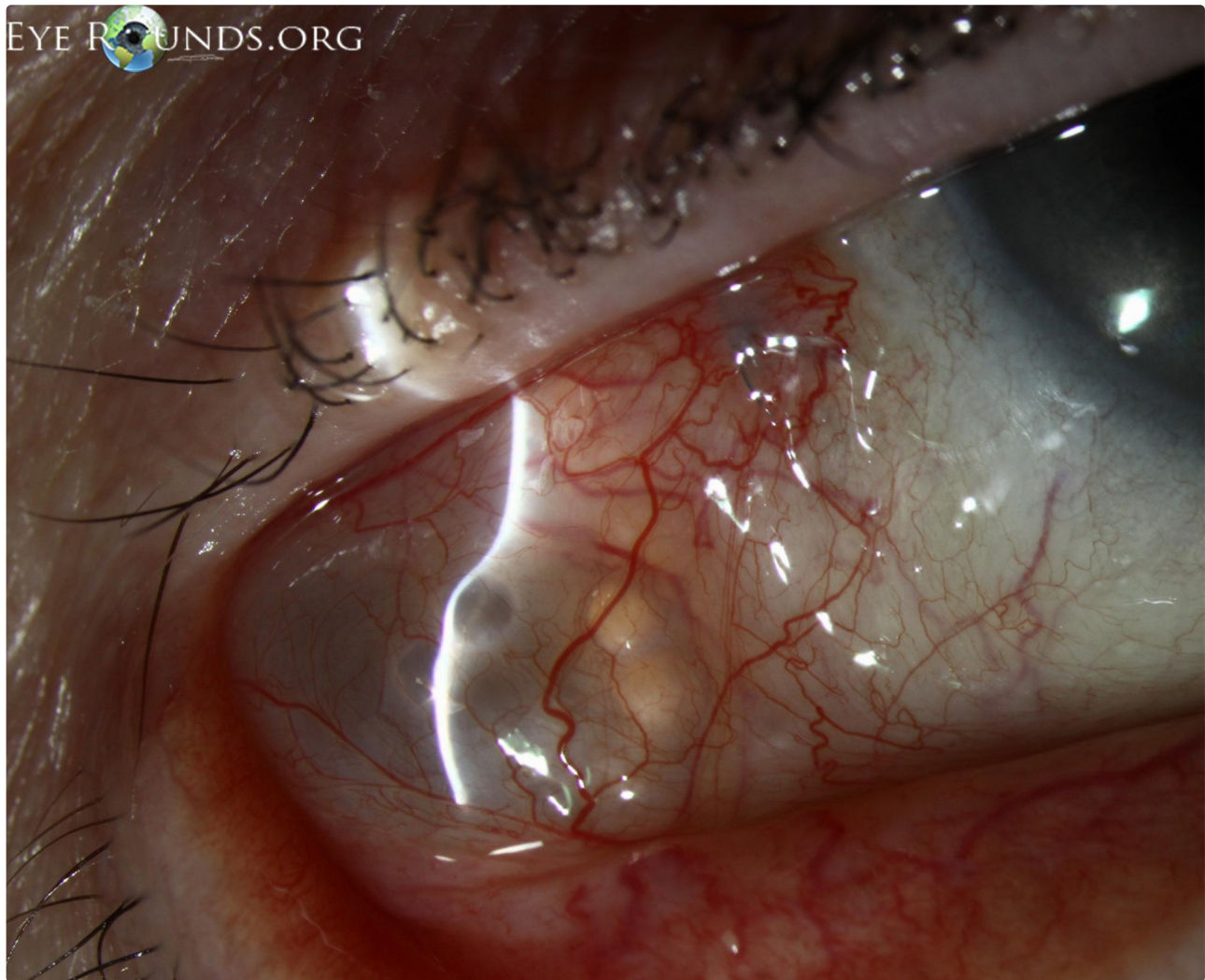
Category(ies): Cornea, External Disease, Vitreous, Retina

Contributor: [Jesse Meredith Baker, MD](#); [Erin Shriver, MD](#)

Photographer: Brice Critser, CRA




89-year-old female status post retinal detachment repair and later removal of silicone oil, now with subconjunctival silicone oil after the procedure (external slit lamp photograph and anterior segment OCT).



External slit lamp photograph

[Enlarge](#)

[Download](#)





anterior segment OC

[Enlarge](#)

[Download](#)

Image Permissions:



Ophthalmic Atlas Images by EyeRounds.org, The University of Iowa are licensed under a [Creative Commons Attribution-NonCommercial-NoDerivs 3.0 Unported License](https://creativecommons.org/licenses/by-nc-nd/3.0/).

Address

University of Iowa
Roy J. and Lucille A. Carver College
of Medicine
Department of Ophthalmology and
Visual Sciences
200 Hawkins Drive
Iowa City, IA 52242

[Support Us](#)

Legal

Copyright © 2019 The University of
Iowa. All Rights Reserved
[Report an issue with this page](#)
[Web Privacy Policy](#) |
[Nondiscrimination Statement](#)

Related Links

[Cataract Surgery for Greenhorns](#)
[EyeTransillumination](#)
[Gonioscopy.org](#)
[Iowa Glaucoma Curriculum](#)
[Iowa Wet Lab](#)
[Patient Information](#)
[Stone Rounds](#)
[The Best Hits Bookshelf](#)

EyeRounds Social Media

Follow



[Receive notification of new cases,
sign up here](#)
[Contact Us](#)
[Submit a Suggestion](#)